

Peripheral Blood Blast Erythrophagocytosis After Chemotherapy in a Patient with Acute Monoblastic Leukemia

Sanae Sayagh^{1,4,*}, Fedoua Cherrafi^{1,4}, Mohammed Siboub^{2,4}, Ilias Tazi^{2,4}, Mustapha Ait Ameur^{3,4}, Mohamed Chakour^{3,4}

¹Hematology Laboratory, University Hospital Mohammed VI, Marrakesh, Morocco

²Onco-hematology Department, University Hospital Mohammed VI, Marrakesh, Morocco

³Hematology Laboratory, Military Hospital of Instruction Avicenne, Marrakesh, Morocco

⁴Faculty of Medicine and Pharmacy, University Cadi Ayyad, Marrakesh, Morocco

Email address:

Sayaghsanae@yahoo.fr (S. Sayagh), fedwa.charafi@gmail.com (F. Cherrafi), simohamedsiboub@hotmail.com (M. Siboub), tazi_illias@hotmail.com (I. Tazi), aitameur.mustapha@yahoo.com (M. A. Ameur), mchakour2005@gmail.com (M. Chakour)

*Corresponding author

To cite this article:

Sanae Sayagh, Fedoua Cherrafi, Mohammed Siboub, Ilias Tazi, Mustapha Ait Ameur, Mohamed Chakour. Peripheral Blood Blast Erythrophagocytosis After Chemotherapy in a Patient with Acute Monoblastic Leukemia. *American Journal of Laboratory Medicine*. Vol. 7, No. 1, 2022, pp. 1-5. doi: 10.11648/j.ajlm.20220701.11

Received: January 5, 2021; **Accepted:** January 4, 2022; **Published:** January 15, 2022

Abstract: Hemophagocytosis is a property of histiocytic lineage cells; it is rarely performed by leukemic blasts. This phenomenon happens in approximately 1% of acute leukemias, particularly acute myeloid leukemia (AML) and especially those of monoblastic or monocytic lineage. Associations have been found with some chromosomal abnormalities, especially t(8;16). The presence of blast hemophagocytosis may speed-up the diagnosis of some of these cytogenetic abnormalities. We aim to report a case of peripheral blood blast erythrophagocytosis after chemotherapy for the treatment of acute monoblastic leukemia. It is about 29 years old male treated for acute monoblastic leukemia without chromosomal abnormalities at the onset, with two relapses for the first and second induction cures. Peripheral blood smear performed during the follow up showed 73% of blasts, 3.6% of them with erythrophagocytosis. Several genetic abnormalities are known to be associated to leukemic cell hemophagocytosis, involving particularly the chromosome 8 and explaining a part of the leukemogenesis. These abnormalities are rare and associated to a poor prognosis. The mechanism behind this blast behavior is still unclear and authors suggest some hypothesis to explain this phenomenon: the presence of binding receptors involved in phagocytosis on blasts, karyotype instability and evolution during the course of the disease and the involvement of treatment toxicity.

Keywords: Blast Erythrophagocytosis, Blast Hemophagocytosis, Acute Monoblastic Leukemia

1. Introduction

Hemophagocytosis is a property of histiocytic lineage cells; it is rarely performed by leukemic blasts. Blast hemophagocytosis must not be confounded with Malignancy related Hemophagocytic Lymphohistiocytosis (M-HLH) occurring generally after chemotherapy and requiring specific diagnosis and treatment.

Blast hemophagocytosis is found in about 1% of acute leukemia, particularly acute myeloid leukemia (AML) and

especially those of a monoblastic or monocytic lineage. It may be associated or not to M-HLH [1]. This phenomenon is more rarely observed in lymphoblastic leukemia [2].

The mechanism behind this blast's behavior remains unclear and associations have been found with some chromosomal abnormalities, especially t(8;16), but also with other translocations as t(10;17), t(16;21), t(3;8;17) and t(3;8) regardless of the morphological type; M0, M1, M4, M5a, M5b or even M7 [1, 3-8]. Many mechanisms have been suggested by authors as the expression of binding receptors involved in hemophagocytosis, karyotype evolution related

to genetic instability and treatment toxicity [2, 3, 6, 9, 10].

Our aim is to report a case of peripheral blood blast erythrophagocytosis after chemotherapy for the treatment of FAB M5a acute monoblastic leukemia without chromosomal abnormalities at the onset and to report the mechanisms trying to explain this phenomenon.

2. Case Report

It is about a previously healthy 29 years old male without medical antecedents except a chronic smoking, admitted to onco-hematology department for abdominal pain and vomiting since a month with fever and alteration of general condition (Table 1). Clinical examination showed a fever at 39°C, mucocutaneous pallor, conjunctival bleeding and tumoral syndrome made of splenomegaly, hepatomegaly and bilateral cervical, axial and inguinal lymphadenopathies. The first peripheral blood examination showed hyperleucocytosis at 90 G/l with 38% of blasts and normochromic normocytic anemia (Hemoglobin: 6,3 g/dl

MCV: 100 fl MCHC: 37 pg) and thrombocytopenia with platelet count at 33 G/l. Bone marrow aspiration showed an infiltration with monoblastic cells HLA-DR+, CD34+, CD33+, CD11c+, CD 36+ and CD 14 +. B and T lymphoid markers were negative except an aberrant expression of CD5 and CD7. The karyotype was normal. The patient was diagnosed as acute monoblastic leukemia without chromosomal abnormalities (M5a) and he was conducted under chemotherapy. The patient relapsed to the first and second induction cures. Following bone marrow aspiration showed blasts infiltration with rare granulations and weak myeloperoxidase and same immunophenotyping found at the time of presentation. Peripheral blood smear showed the presence of 73% of blasts, 3.6% of them presented erythrophagocytic (Figure 1). The blasts contained both single and double cytoplasmic vacuoles occupying a large part of the cytoplasm and mimicking the aspect of red blood cells. The second karyotype weren't performed since the patient lost to follow-up.

Table 1. Diagnosis data of the patient.

Antecedents	Chronic smoking		
Clinical data	Fever at 39°, mucocutaneous pallor, tumoral syndrome		
Biological data	Complete Blood Count Bone marrow aspiration Karyotype	At the time of presentation	After induction cures
		WBC 90G/l Blasts 38%	Blasts 73%, Erythrophagocytosis in 3,6%
		Cytology: Monoblastic cells Immunophenotyping: HLA-DR+, CD34+, CD33+, CD11c+, CD36+, CD14+	Same immunophenotyping
		Lymphoid markers B and T negative except CD5 and CD7 Normal	-

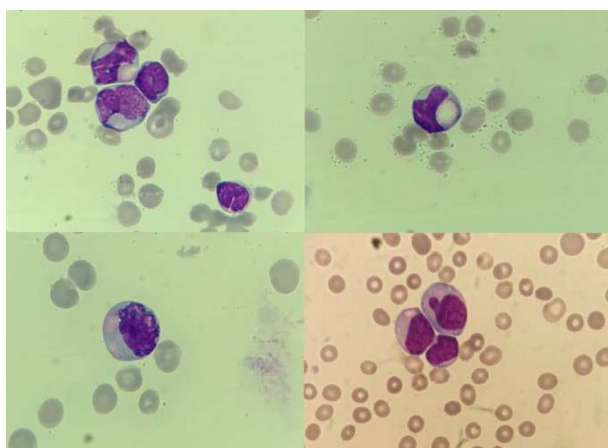


Figure 1. Peripheral blood blast erythrophagocytosis. MGG staining (x1000).

3. Discussion

To our knowledge, no case has been reported of blast hemophagocytosis in peripheral blood smear. In the bone marrow, this phenomenon may interest all types of hematopoietic cells; erythrocytes, platelets, leucocytes and even blasts [11].

Blast hemophagocytosis is frequently reported during

monoblastic/monocytic acute leukemia, rarely in other types of acute myeloid leukemia as M0, M1, M2 and M7 and it is unusual in acute lymphoblastic leukemia [1-3, 9, 11, 12]. This phenomenon is not considered to distinguish between acute monoblastic leukemia and other type of leukemia. It may also be present in non-hematopoietic malignancies [13].

Blast hemophagocytosis is mostly reported at the time of the onset and is associated to abnormal karyotype [1, 3-9, 11], it rarely happens after chemotherapy, as in our case, and seems to be associated to karyotype evolution in patients presenting with normal karyotype at the onset [1].

The percentage of blasts involved may vary extremely, from 0.2 to 36.7% [1, 3-9, 11]. The specificity of blast hemophagocytosis is controversial and cases reported in the literature do not mention any specific explorations or dedicated treatment as in M-HLH [3, 11, 13].

It remains important to us to understand the mechanism related to this phenomenon, its implication in cytogenetic diagnosis and prognosis.

Hemophagocytosis by leukemic cells or blasts must not be confounded with M-HLH, even if both phenomenon may be present in the same patient [1].

The pathogenic mechanism related to leukemic cells with phagocytic activity remains unclear. Phagocytosis is defined by the ingestion of particles following two steps; binding and

ingestion. But receptors involved in binding, like Fc receptor, are not normally present in myeloblasts; Park et al suppose that more complex factors are involved in blast hemophagocytosis other than the presence or not of Fc receptors and Yeh et al postulate this may be related to the presence of C3 receptor, expressed in leukemic blasts of AML, which binds blast cells to erythrocytes known by expressing the receptor for C3b and leading to erythrophagocytosis [2, 6].

Blast hemophagocytosis seems to be associated to some specific genetic abnormalities diagnosed at the onset or during the course of the disease (Table 2) [3]. Translocation t(8;16) (p11;p13) is frequently reported in acute monoblastic leukemia with hemophagocytosis by leukemic cells and more rarely the translocations t(3;8;17) and t(3;8) (q27;q22) [1, 4, 9]. In fact, the chromosome 8 rearrangement in 8p11 region is frequently implicated in monocytic AML with hemophagocytosis and seems to play also a role in leukemogenesis [3]; abnormalities of MYST 3 gene situated in this region may improve myelomonocytic proliferation by increasing related growth factors as M-CSF and G-CSF, hemophagocytosis may be a consequence of cytokines and growth factors dysregulation as INF γ , M-CSF, GM-CSF [9, 10].

AML with t(8;16) (p11;p13) is described in many reports as a myeloid leukemia containing hemophagocytic blasts [3, 7, 8]. Erythrophagocytosis activity may involve 1.8 to 2% of

nucleated bone marrow cells including blasts [8].

Other translocations have been reported in cases of hemophagocytosis by myeloid blasts as the t(16;21) (p11;q22) and t(10;17) (p13;q12) [3, 11]. Shikami et al demonstrated that leukemic cells with t(16;21) continue to express some stem cell antigens as CD34 and c-kit with possible differentiation into monocytic lineage enabling blasts to hold phagocytic activity [12, 14].

Imashuku S and al suggest that the presence of blast hemophagocytosis may speed up the diagnosis of t(16;21) (p11;q22). They report 12 cases of AML with t(16;21) all with blast hemophagocytosis in the bone marrow [3]. Blieden et al suppose that the presence of monocytoid blast morphology with erythrophagocytosis suggested the presence of the t(8;16) in this AML [5]. Close association between this morphologic feature and cytogenetic abnormalities may be useful.

Complex karyotype has been also reported in acute myeloid leukemia with monocytoid blasts and erythrophagocytosis [5].

Very few cases of lymphoblastic hemophagocytosis have been reported [2, 15], one case with the t(12;21) (p13;q22); TEL-AML1 (ETV6-RUNX1) [2]. This phenomenon may be explained by the presence of the Fc receptor in blasts of lymphoid lineage [2]. All these genetic abnormalities seem to be associated to poor response to therapy and poor prognosis [1, 3, 10-12].

Table 2. Cytogenetic abnormalities and percentage of blasts involved in acute myeloid leukemia reported with blast hemophagocytosis.

Number of cases	Cytogenetic abnormalities	FAB type	At the onset/after chemotherapy	Percentage of blasts involved	Reference
1	Normal karyotype at the onset Complex karyotype after chemotherapy	-	After chemotherapy	-	[1]
7	t(16;21) (p11;q22)	M1 (5) M7 (1) M5b (2)	At the onset	0,2-36,7%	[3]
1	t(3;8;17) (q27;p11;q12)	M5	At the onset	-	[4]
1	t(8;16) (p11;p13)	-	At the onset	-	[5]
1	Near-tetraploidy	M0	At the onset	-	[6]
3	t(8;16) (p11;p13)	M4	At the onset	-	[7]
3	t(8;16) (p11;p13)	M5b	At the onset	1.8-2%	[8]
1	t(3;8) (q27;q22)	M5a	At the onset	20%	[9]
2	t(10;17) (p13;q12)	M7	At the onset	0.3% 3%	[11]

Hemophagocytosis by leukemic blast may be found at the onset of the disease or during the treatment like in our case, the apparition of cytogenetic abnormalities in a patient with a normal karyotype at the initial presentation may be related to high genetic instability and chemotherapy toxicity [1, 16]. In fact, evolution to more complex karyotype has been shown in 53% of myeloid leukemia [16].

Many authors suggest the implication of the chemotherapy in the appearance of blast hemophagocytosis [1, 16]; Farias et al suggest this phenomenon to be explained by the cytogenetic aberrations, sometimes complex, acquired after chemotherapy [1]. For Foadi et al, prolonged chemotherapy expose cells to a variety of drugs and alterations and may contribute to the appearance of more aggressive clone of

leukemic cells with phagocytic features in cases of lymphoid blast hemophagocytosis [17].

Unlike blast hemophagocytosis, M-HLH is generally reported after chemotherapy. In the M-HLH, hemophagocytosis is performed by cells of histiocytic lineage and is largely explained by the immune dysregulation of T lymphocytes and natural killer or immune suppression caused in part by the treatment and resulting in the pro-inflammatory cytokines release and excessive activation of hemophagocytic monocytes, associated to fatal infections especially in patients who have already achieved remission [18, 19]. It is a serious and life-threatening acute complication due to the treatment of different malignancies [19, 20].

The HLH Study Group of the Histiocyte Society proposed diagnostic guidelines for HLH; five of this eight criteria must be fulfilled: fever, splenomegaly, cytopenia, hypertriglyceridemia and/or hypofibrinogenemia, hemophagocytosis, low or absent Natural killer cell activity, hyperferritinemia, and high soluble interleukin 2 receptor (s-IL2-receptor) [21]. Early diagnosis and immediate initiation of adequate treatment are mandatory to overcome this severe condition [20].

Unlike M-HLH, no specific treatment is administered to patients with hemophagocytic blasts in all reported cases, considering, indirectly, this phenomenon as a “normal” behavior of leukemic cells without specific treatment implications. Further explorations related to HLH are also not indicated for those patients.

4. Conclusion and Recommendations

Phagocytic activity in leukemic blasts is a very rare phenomenon, it may be closely linked to some cytogenetic abnormalities and explain a part of the leukemogenesis. Morphology examination is still relevant and may provide a useful orientation to this type of abnormalities. The mechanism behind this phenomenon is still unclear and few hypotheses have been proposed in the literature. To date, no specific explorations or treatment are dedicated to this morphologic feature.

Further investigations are necessary to determine the precise mechanism behind this behavior and its implications on the prognostic and treatment.

Conflict of Interest

All the authors do not have any possible conflicts of interest.

References

- [1] Farias MG, Correa Freitas PA, Spagnol F, de Souza MV, Alegratti AP, Riegel M, Nori Rodrigues Taniguchi A, Esteves Daudt L. Hemophagocytosis by blasts in a child with acute monocytic leukemia after chemotherapy. *Rev Paul Pediatr* 2021; 39 [in press].
- [2] Park JE, Park IJ, Lim YA, Lee WG, Cho SR. Hemophagocytosis by Leukemic Blasts in B Lymphoblastic Leukemia with t(12;21) (p13;q22); TEL-AML1 (ETV6-RUNX1): a Case Report. *Annals of Clinical & Laboratory Science* 2013; 43: 186–9.
- [3] Imashuku S, Hibi S, Sako M, Lin YW, Ikuta K, Nakata Y, Mori T, Lizuka S, Horibe K, Tsunematsu Y. Hemophagocytosis by Leukemic Blasts in 7 Acute Myeloid Leukemia Cases with t(16;21) (p11;q22): Common Morphologic Characteristics for This Type of Leukemia. *Cancer* 2000; 88: 1970–5.
- [4] Bertheas MF, Jaubert J, Vasselon C, Reynaud J, Pomier G, Le Petit JC, Hagemeijer A, Brirard CP. A Complex t (3; 8; 17) Involving Breakpoint 8p11 in a Case of M5 Acute Nonlymphocytic Leukemia with Erythrophagocytosis. *Cancer Genet Cytogenet* 1989; 42: 67–73.
- [5] Blieden C, Fan Y, Chapman JR, Vega F. De novo acute myeloid leukemia with monocytoid blasts and erythrophagocytosis. *Clinical Case Reports* 2014; 2 (6): 333–5.
- [6] Yeh SP, Wang YC, Su JL, Hsueh EJ, Yu MS, Wu H. Near tetraploid minimally differentiated acute myeloid leukemia with extensive erythrophagocytosis by leukemia blasts. *Ann Hematol* 2000; 79: 36–9.
- [7] Lai JL, Zandecki M, Jouet JP, Savary JB, Lambilliotte A, Bauters F, et al. Three cases of translocation (8;16) (p11;q13) observed in acute myelomonocytic leukemia: a new specific subgroup? *Cancer Genet Cytogenet* 1987; 27: 101–9.
- [8] Heim S, Avanzi GC, Billstrom R, Kristoffersson U, Mandahl N, Bekassy AN, et al. A new specific chromosomal rearrangement t(8;16) (p11;p13) in acute monocytic leukaemia. *Br J Haematol* 1987; 66: 323–6.
- [9] El Borgi W, Gouider E, Louati N, Ben Salah N, Senana H, Jeddi R, Saad A, Hafsia R. Hémophagocytose au cours d’une leucémie aiguë monoblastique avec une translocation t(3;8) (q27;q22): à propos d’un cas et revue de la littérature. *Hématologie* 2010; 16: 96–9.
- [10] Murati A, Chaffanet M, Mozziconacci MJ, Birnbaum D. Leucémies aiguës myéloïdes et altérations de MYST3. *Hématologie* 2008; 14: 151–60.
- [11] Lai JL, Estienne MH, Fenaux P, Lepelletier P, Huart J, Bauters F, Deminatti M. Translocation t(10;17) (p13;q12) in Two Cases of Acute Nonlymphocytic Leukemia with Phagocytic Activity of Blasts A New Cytogenetic Entity? *Cancer Genet Cytogenet* 1989; 39: 45–53.
- [12] Harrison A, Chandra D, Kakkar N, Das S, Joseph John M. Hemophagocytosis by Leukemic Blasts in T Cell Acute Lymphoblastic Leukemia: An Unusual Finding. *Indian J Hematol Blood Transfus* 2016; 1Suppl: 23–5.
- [13] Wheeler MS, Wilson EC, Stass SA. Erythroleukophagocytosis by leukemic cells: a nonspecific finding [letter]. *Am J Clin Pathol* 1981; 75: 266–7.
- [14] Shikami M, Miwa H, Nishii K, Takahashi T, Shiku H, Tsutani H, Oka K, Hamaguchi H, Kyo T, Tanaka K, Kamada N, Kita K. Myeloid differentiation antigen and cytokine receptor expression on acute myelocytic leukaemia cells with t(16;21) (p11;q22): frequent expression of CD56 and interleukin-2 receptor α chain. *British Journal of Haematology* 1999; 105: 711–9.
- [15] Klein E, Derrieux C, Dulucq S. Hemophagocytosis by blasts in acute lymphoblastic leukemia. *Blood Research* 2019; 54 (1): 2.
- [16] Garson OM, Hagemeijer A, Sakurai M, Reeves BR, Swansbury GJ, Williams GJ, et al. Cytogenetic studies of 103 patients with acute myelogenous leukemia in relapse. *Cancer Genet Cytogenet*. 1989; 40: 187–202.
- [17] Foadi MD, Slater AM, Pegrum GD. Erythrophagocytosis by acute lymphoblastic leukaemic cells. *Scand J Haematol* 1978; 20: 85–8.
- [18] Strenger V, Merth G, Lackner H, Aberle SW, Kessler HH, Seidel MG, Schwinger W, Sperl D, Sovinz P, Karastaneva A, Benesch M, Urban C. Malignancy and chemotherapy induced haemophagocytic lymphohistiocytosis in children and adolescents—a single centre experience of 20 years. *Annals of Hematology* 2018; 97: 989–98.

- [19] Lackner H, Seidel MG, Strenger V, Sovinz P, Schwinger W, Benesch M, Sperl D, Urban C. Hemophagocytic syndrome in children with acute monoblastic leukemia-another cause of fever of unknown origin. *Support Care Cancer* 2013; 21: 3519-23.
- [20] Lackner H, Urban C, Sovinz P, Benesch M, Moser A. Hemophagocytosis lymphohistiocytosis as severe adverse event of antineoplastic treatment in children. *Haematologica* 2008; 93 (2): 291-4.
- [21] Henter JI, Horne A, Aricó M, Egeler RM, Filipovich AH, Imashuku S. HLH-2004: Diagnostic and therapeutic guidelines for hemophagocytic lymphohistiocytosis. *Pediatr Blood Cancer*. 2007; 48: 124-31.